

Improvement in Lupus Nephritis Following Treatment With a Chinese Herbal Preparation

Hui-Kim Yap, MBBS, MMed(Pediatrics), FRCP(Edin), MD; Siau-Gek Ang, BSc(Hon), PhD; Yee-Hing Lai, BSc, PhD; Vinod Ramgolam, BSc, MSc; Stanley C. Jordan, MD

Objective: To study the effect of a Chinese herbal decoction (CM), which contained 21 different herbs, on clinical remission in a patient with lupus nephritis and chronic nephrotic syndrome.

Design: Case report describing the clinical and laboratory markers of lupus activity in the patient before and after treatment with CM. We also studied the in vitro effect of CM and its hydrophobic extract on spontaneous IgG production by peripheral blood mononuclear cells (PBMCs) from 12 patients with systemic lupus erythematosus (SLE) compared with 9 healthy control subjects.

Results: Spontaneous PBMC IgG production was significantly higher in patients with SLE (mean \pm SD,

$20.4 \pm 10.6 \times 10^{-5}$ g/L) compared with controls ($4.7 \pm 1.9 \times 10^{-5}$ g/L) ($P < .001$). Addition of CM and its hydrophobic extract to PBMCs from patients with SLE resulted in significant suppression of spontaneous IgG production.

Conclusions: The CM may contain some active pharmacological compound with immunosuppressive properties useful in the treatment of SLE. Further controlled studies are important to evaluate the efficacy of this medicine, potential toxic effects, and the possible immunosuppressive mechanisms of the active component(s).

Arch Pediatr Adolesc Med. 1999;153:850-852

Editor's Note: It's always difficult to determine cause-effect on an *n* of 1. However, when Dr Yap told me about this patient, I found it sufficiently compelling to warrant peer review, and (as it turned out) publication. Stay tuned.

Catherine D. DeAngelis, MD

CURRENT TREATMENT protocols for systemic lupus erythematosus (SLE) involve the use of various immunosuppressive agents with a multitude of serious side effects.^{1,2} Such therapeutic regimens include high-dose corticosteroids with their effect on growth in children, cataract formation, nonspecific immune suppression with increased risk for unusual infections, hypertension, and osteoporosis. Often, cytotoxic drugs, such as cyclophosphamide, chlorambucil, or azathioprine, may be required to control disease activity, bringing with them a multitude of adverse effects such as bone marrow suppression, hepatic toxic effects, sterility, and risk for malignant neoplasms.

Herbal medicines have been used to treat rheumatic diseases for centuries in China. These include the vinelike plant *Trip-*

terygium wilfordii Hook-f³⁻⁵ and extracts of the tuberous root of the creeper *Stephania tetrandra*.⁶ Today, substances derived from plants constitute about 25% of drugs used in conventional medical therapy.⁷ The search continues for the ideal immunosuppressive drug with minimal adverse effects.

We herein describe a patient with lupus nephritis and chronic nephrotic syndrome, in whom clinical remission started after ingestion of a Chinese herbal decoction (CM) that contained 21 different herbs.

RESULTS

After 4 months of CM therapy, when our patient returned for follow-up (**Figure 1**), she was noted to be edema free, with blood pressure at 120/75 mm Hg (within normal limits). Her laboratory features continued to improve during the next few months, with a urinary protein excretion of 1.3 g/d per 1.73 m², serum albumin level of 30 g/L, serum creatinine level of 61 μ mol/L (0.7 mg/dL), erythrocyte sedimentation rate of 25 mm/h, C3 level of 100 mg/dL, and C4 level of 24.7 mg/dL (**Figure 2**). Her anti-double stranded DNA antibody level decreased to 11 mg/L. Subsequently, her

From the Departments of Pediatrics (Drs Yap and Ramgolam) and Chemistry (Drs Ang and Lai), National University of Singapore, Singapore; and the Division of Pediatric Nephrology, Department of Pediatrics, University of California, Los Angeles—Cedar Sinai Medical Center (Dr Jordan).

SUBJECTS AND MATERIALS

REPORT OF PATIENT

A 16-year-old Chinese girl presented with features of SLE at the age of 7 years. Her initial clinical manifestations were prolonged pyrexia for 1 month, arthralgia, and erythematous rash over the malar region. She had oral ulcerations and hepatosplenomegaly. Her blood pressure was within normal limits at 120/80 mm Hg. Laboratory findings included hemoglobin of 120 g/L, white blood cell count of $5.6 \times 10^9/L$ (0.67 neutrophils, 0.10 lymphocytes, and 0.03 monocytes), and platelet count of $50 \times 10^9/L$. The erythrocyte sedimentation rate was 110 mm/h; results of direct Coombs test, positive; serum total hemolytic complement (CH_{50}) level, 13 U (normal range, 20-50 U); anti-nuclear antibody titer, 1:1280 (homogeneous pattern); and anti-double stranded DNA antibody, greater than 15 mg/L (normal, <5 mg/L). Results of urinalysis did not reveal any microscopic hematuria, but proteinuria was present (1+). High-dose prednisolone therapy at 60 mg/d was started until the fever and arthralgia resolved. The prednisolone therapy was then slowly tapered to a maintenance dosage of 10 mg/d.

At the age of 12 years, the nephrotic syndrome developed, with generalized edema, urinary total protein excretion of 1.7 g/d per 1.73 m², and low serum albumin level of 25 g/L. Her renal function was normal, with a serum urea level of 8 mmol/L (48 mg/dL), and serum creatinine level of 60 $\mu\text{mol/L}$ (0.7 mg/dL). She refused a renal biopsy, as well as any increase in her dose of prednisolone or additional cytotoxic drugs such as azathioprine or cyclophosphamide. During the next 4 years, her nephrotic state worsened, with an increase in the urinary protein excretion to 13.4 g/d per 1.73 m² and a decrease in the serum albumin level to 11 g/L. Hypertension subsequently developed, with a blood pressure of 160/110 mm Hg and a rise in serum creatinine level to 132 $\mu\text{mol/L}$ (1.5 mg/dL). She also had serological markers of active lupus, with an erythrocyte sedimentation rate of 108 mm/h, C3 level of 58.5 mg/dL (normal range, 83-177 mg/dL), C4 level of 15 mg/dL (normal range, 15-45 mg/dL), and anti-double stranded DNA

antibody level of greater than 15 mg/L. She again refused a renal biopsy and any increase in her immunosuppressive therapy. Instead, she took the CM twice daily, together with prednisolone at 10 mg/d.

PREPARATION OF CM AND ITS HYDROPHOBIC EXTRACT FOR IN VITRO STUDIES

The CM prescribed for the patient was boiled in water in the traditional manner. After filtration to remove insoluble material, the solution obtained was lyophilized to give a solid weight of 0.1105 g/mL of solution. The CM was subsequently subjected to methanol reflux and concentrated by partitioning the methanol extract between ethyl acetate and water. The active hydrophobic extract (EX) was found in the organic layer.

IN VITRO STUDIES OF THE EFFECT OF CM ON LYMPHOCYTE IgG PRODUCTION

Peripheral blood mononuclear cells (PBMCs) were isolated from 12 patients with SLE and 9 healthy control subjects using Ficoll-diatrizoate sodium density centrifugation (Ficoll-Paque; Pharmacia LKB Biotechnology Inc, Uppsala, Sweden). Informed consent was obtained from the parents before blood sampling. The PBMCs were cultured in RPMI 1640 (GIBCO, Grand Island, NY) supplemented with 10% heat-inactivated fetal calf serum, 2-mmol/L L-glutamine, 125-mg/mL streptomycin, and 125-U/mL penicillin. Cell viability was greater than 90% as assessed by the trypan blue method. The PBMCs were cultured with complete media alone, with ethanol as the solvent, 440 $\mu\text{g/mL}$ of CM and the EX. This was based on a dose-response curve obtained after studying the effect of CM on the supernatant IgG production from pokeweed mitogen-stimulated PBMCs in healthy subjects. Here, a CM concentration of 440 mg/mL resulted in maximal suppression. The supernatants were harvested on day 12, and the supernatant IgG levels were measured by standard enzyme immunoassay technique. The *t* test (2 tailed) was used to assess the difference between the groups. Unless otherwise indicated, data are given as mean \pm SD.

prednisolone dosage could be tapered to 5 mg/d, without any increase in the lupus activity. No adverse effects in terms of bone marrow depression or liver toxicity effects were noted with the use of CM.

In our in vivo studies, spontaneous PBMC IgG production was significantly higher in patients with SLE ($20.4 \pm 10.6 \times 10^{-5}$ g/L) compared with controls ($4.7 \pm 1.9 \times 10^{-5}$ g/L) ($P < .001$). As shown in **Figure 3**, addition of CM and EX to PBMCs from patients with SLE resulted in significant suppression of spontaneous IgG production, with levels of $9.5 \pm 4.8 \times 10^{-5}$ g/L and $7.4 \pm 4.2 \times 10^{-5}$ g/L, respectively, compared with ethanol alone ($21.7 \pm 9.3 \times 10^{-5}$ g/L) ($P < .001$).

COMMENT

The potential of higher plants as sources of new drugs is well recognized, and current medical research is

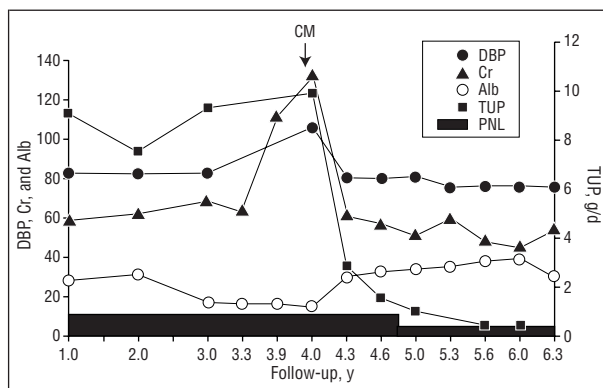


Figure 1. Effect of the Chinese herbal decoction (CM) on the clinical course of a patient with lupus nephritis. DBP indicates diastolic blood pressure; Cr, serum creatinine level; Alb, serum albumin level; TUP, total urinary protein level; and PNL, daily prednisolone dose. Shaded region indicates PNL (measured in milligrams per day). DBP is measured in millimeters of mercury; Cr, in micromoles per liter; and Alb, in grams per liter.

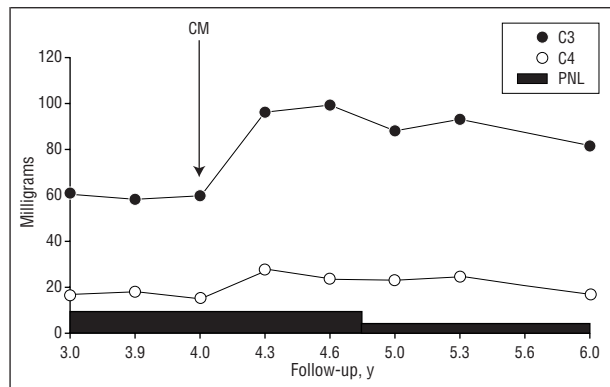


Figure 2. Effect of the Chinese herbal decoction (CM) on serum complement (C) levels in a patient with lupus nephritis. PNL indicates daily prednisolone dose. Complement levels are measured in milligrams per deciliter; prednisolone, in milligrams per day.

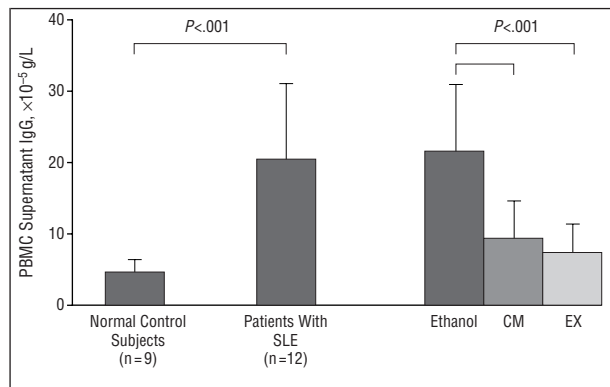


Figure 3. Effect of the Chinese herbal decoction (CM) and its hydrophobic extract (EX) on IgG production by peripheral blood mononuclear cells (PBMCs) in patients with systemic lupus erythematosus (SLE). Limit lines indicate SDs.

directed at exploring the biological and pharmacological properties of many of these plant species. Our CM is a decoction of 21 herbs that has been used in the treatment of rheumatic diseases for centuries in China. These herbs are from the genera *Prubella*, *Lycium*, *Bletilla*, *Ligustrum*, *Dianthus*, *Myrrha*, *Eucommia*, *Rehmannia*, *Rosa*, *Rubia*, *Imperata*, *Curculigo*, *Panax*, *Astragalus*, *Codonopsis*, *Dioscorea*, *Nelumbo*, *Boswellia*, *Polygonum*, *Citrus*, and *Glycyrrhiza*. Of these, *Astragalus chinensis*, *Rehmannia glutinosa*, and *Eucommia ulmoides* have been reported in the Chinese pharmacopeia to be active as antirheumatic agents. Our patient with SLE had long-standing nephrotic syndrome with severe proteinuria of 13.4 g/d per 1.73 m². Although results of renal histological studies were not available, development of hypertension and a rising serum creatinine level accompanied by low serum complement levels were harbingers of progressive lupus activity. The patient's clinical and serological features im-

proved dramatically after starting therapy with CM. At this time, she only received 10 mg/d of prednisolone. As the prednisolone dose was not increased during this period, it could not account entirely for the notable improvement in the nephrotic state of the patient. Although it is conceivable that the lupus nephritis went into spontaneous remission, this was unlikely in view of the chronicity of the nephrotic syndrome before the ingestion of CM. The CM may have a synergistic action with prednisolone in inducing clinical improvement of the nephrotic state and the lupus activity.

In patients with active SLE, in vitro spontaneous PBMC production of IgG has been shown to be increased in previous studies.⁸ Our study showed that CM and EX were able to suppress considerably the elevated spontaneous IgG production by PBMCs in patients with SLE. Hence, CM and EX have in vitro immunosuppressive activity and may be useful in the treatment of SLE. Further work is being performed to characterize the compound(s) in this decoction that may confer biological activity.⁹

Accepted for publication December 22, 1998.

This work was supported in part by grants RP930319 from the National University of Singapore and NMRC0223/1997 from the National Medical Research Council, Singapore.

We thank Seah Ching Ching for technical assistance.

Corresponding author: Hui-Kim Yap, MBBS, MMed (Pediatrics), FRCP(Edin), MD, Department of Pediatrics, National University Hospital, Lower Kent Ridge Road, Singapore 119074 (e-mail: paeyaphk@nus.edu.sg).

REFERENCES

1. Cameron JS. The treatment of lupus nephritis. *Pediatr Nephrol.* 1989;3:350-362.
2. Donadio JV Jr, Glassock RJ. Immunosuppressive drug therapy in lupus nephritis. *Am J Kidney Dis.* 1993;21:239-250.
3. Yu D. Clinical observation of 144 cases of rheumatoid arthritis treated with glycosides of *Tripterygium wilfordii*. *J Tradit Chin Med.* 1983;3:125-129.
4. Wang BX, Yuan ZZ. A tablet of *Tripterygium wilfordii* in treating lupus erythematosus. *Chin J Modern Dev Tradit Med.* 1989;9:407-408.
5. Kao NL, Richmond GW, Moy JN. Resolution of severe lupus nephritis associated with *Tripterygium wilfordii* hook F ingestion. *Arthritis Rheum.* 1993;36:1751-1752.
6. Chen KK, Chen AL. The alkaloids of Han-Fang-Chi. *J Biol Chem.* 1935;109:681-685.
7. Hamburger M, Hostettmann K. Bioactivity in plants: the link between phytochemistry and medicine. *Phytochemistry.* 1991;30:3864-3874.
8. Wigfall DR, Sakai RS, Wallace DJ, Jordan SC. Interleukin-2 receptor expression in peripheral blood lymphocytes from systemic lupus erythematosus patients: relationship to clinical activity. *Clin Immunol Immunopathol.* 1988;47:354-362.
9. Yap HK, Zuo XJ, Toyoda M, et al. Immunosuppressive effect of the hydrophobic extract of a Chinese herb on rat lung allograft rejection. *Transplant Proc.* 1998;30:980-981.